Clinical and functional outcomes of laminoplasty and laminectomy

Julian Hardman*, Oliver Graf*, Pelagia E. Kouloumberis*, Wei-Hua Gao†, Michael Chan* and Ben Z. Roitberg‡

**Department of Neurosurgery, School of Medicine, and †Department of Biostatistics, School of Public Health, University of Illinois at Chicago, Chicago IL, USA*
‡Section of Neurosurgery, University of Chicago, Chicago IL, USA

Objective: Laminoplasty has become a common alternative to laminectomy for cervical spondylotic myelopathy or radiculopathy. The procedures have been compared before, but data on functional recovery are limited. We aim to compare the safety and short-term clinical and functional outcomes of cervical laminoplasty and cervical laminectomy.
Methods: We performed a retrospective analysis of the outcome of 72 patients who had laminoplasty and 49 patients who had laminectomy at our hospital from 1999 to 2005. Patients had cervical spondylotic myelopathy or radiculopathy. All of the patients were similar in age and pre-operative functional status. All patients were assessed pre-operatively and 4 months post-operatively with the Rankin disability score, Glasgow outcome scale and Karnofsky and Nurick scales.
Results: Laminoplasty resulted in greater improvement than laminectomy on the Rankin scale ($p<0{\cdot}0001$, chi-square test), GOS ($p<0{\cdot}0027$, chi-square test) and Karnofsky scores ($p<0{\cdot}01$, Wilcoxon test). Nurick scores improved in both groups without a significant difference ($p<0{\cdot}62$, Wilcoxon test). The proportion of patients who improved on all scales tended to be greater in the laminoplasty group. Patients spent 1·8 fewer days in the hospital after laminoplasty ($p=0{\cdot}04$, Wilcoxon rank-sum test). There was no mortality or permanent morbidity for either procedure.
Conclusion: Both cervical laminectomy and laminoplasty are safe and effective for the treatment of cervical myelopathy or radiculopathy. Cervical laminoplasty results in a shorter hospital stay and greater functional improvement at 4 months follow-up.

Keywords: Laminoplasty, laminectomy, GOS, Karnofsky, Rankin, Nurick, length of stay

Published by Maney Publishing (c) W. S. Maney & Son Limited

Introduction

Before the development of cervical laminoplasty, many patients with cervical spondylotic myelopathy or radiculopathy had been treated with a multilevel laminectomy. This treatment generally has satisfactory outcomes based on the Nurick scale or the Japanese Orthopaedic Association Scale, but may result in spinal instability in the longer term[1–5]. The laminoplasty technique was introduced in Japan by Hattori in 1971[6]. The intent was to perform a more conservative procedure that maintains some of the posterior element structure and function. Since its introduction, laminoplasty has become a common alternative to laminectomy for cervical spondylotic myelopathy or radiculopathy. Excellent results have been reported for the use of this technique. Laminoplasty was chosen because of presumed greater cervical spine stability, better functional outcomes and fewer complications[7–9]. Despite presumed advantages, cervical laminoplasty is not uniformly accepted, and controversy regarding the relative merits of laminoplasty and laminectomy persists. In this retrospective analysis, we compare open door cervical laminoplasty with laminectomy. The two procedures have been compared previously, but data on early functional recovery have been limited. Hypothetically, the less destructive nature of laminoplasty may result in a shorter time to recovery. We aimed to study the early recovery after laminoplasty and laminectomy.

Subjects and methods

From May 1999 to December 2005, 72 patients who had laminoplasty and 49 patients who had laminectomy at our institution were included in this retrospective analysis. All of the patients were diagnosed with cervical spondylotic myelopathy or radiculopathy. This period was chosen because, at this time, some of the surgeons at our institution performed laminectomy and others performed laminoplasty for the same indications. Thus, patients were available for direct comparison between the two techniques. In a chart review, we were limited to information

Correspondence and reprint requests to: Ben Z. Roitberg, MD, University of Chicago Medical Center, 5841 S. Maryland, MC 3026, Chicago, IL 60637, USA. [broitber@surgery.bsd.uchicago.edu] Accepted for publication May 2009.

© W. S. Maney & Son Ltd 2010
DOI 10.1179/174313209X459084

Published by Maney Publishing (c) W. S. Maney & Son Limited

collected normally in the process of treatment. Thus, we had to find a way to record an objective measure of patients' clinical recovery. Several clinical scales were used to provide for a uniform description of the patient's condition. Although they were not originally developed to evaluate spine patients, these scales provide a way to assign a number to the clinical evaluation of function and disability. Independent observers who were not involved in patient care reviewed the charts and recorded the scores. True blinding is not possible in a retrospective chart review of this type. Modified Rankin scale[10] was used (range: 0–6, with 0 being normal and 6 being dead). Patients who had myelopathy included in their diagnosis were also evaluated with the Nurick scale (range: 0–5, with 0 being normal and 5 being chairbound or bedridden). Glasgow outcome score (GOS) was used to evaluate all patients. We also used the Karnofsky scale of daily activities (range: 0–100, with 0 being dead and 100 being normal with no complaints). Although the Karnofsky scale has not previously been validated specifically for spine patients, we felt that, as one of several measures rather than a stand-alone parameter and pertaining to patients' quality of life, it is a relevant measurement. Patients who had cervical spine fusion or instrumentation procedures in addition to laminoplasty or laminectomy were excluded.

The variables collected included age, gender, diagnosis, operative date, attending surgeon, procedure performed, pre-operative physical status, pre-operative Karnofsky score, pre-operative Nurick score, pre-operative Rankin score, post-operative physical status, post-operative Karnofsky score, post-operative Nurick score, post-operative Rankin score, GOS, complications, days until discharge, post-operative pain, intravenous drugs used and discharge location. All the information was collected from the patients' charts. Independent observers not involved with the care of the patients performed all the chart analyses.

Laminoplasty procedure is as follows. We recognize the fact that many variants of laminoplasty have been reported. At our institution, laminoplasty is performed at C3–C7 levels. The head is placed in a neutral position in a Mayfield clamp. After a carefully measured midline incision, the spinous processes and laminae of C3–C7 are exposed, and a Horsley bone cutter is used to remove the spinous processes. All the soft tissues are removed from the spinous processes, and the two largest ones (C6 and C7) are used to prepare structural grafts. A trough is drilled at the lamina–facet joint on the less symptomatic side using a Midas–Rex drill with an M8 cutting bit. The trough involves the outer cortical layer and cancellous bone but not the inner cortex. The contralateral lamina–facet junction is drilled from C3 to C7 down to the ligamentum flavum. The laminae are then reflected *en bloc*, bending but not fracturing the bone; the previously created structural grafts are placed between them. Two grafts are typically used and placed at the two locations that will hold up all five segments. Infrequently, we use a third bony strut, or use allografts and miniplates when autograft appears inadequate for stability of the construct. The remaining ligamentum flavum is visualized underneath at all levels. Along with the remaining interspinous ligament, they behave as a tension band. This technique also allows foraminotomies to be performed as needed. The remaining previously removed spinous processes are morselized and placed in the gutter of the hinge side in order to serve as the fusion mass. Laminoplasty allows for posterior decompression while providing an osseous covering for the spinal cord[11].

Laminectomy starts similar to the laminoplasty procedure, but drilling at the gutters is performed bilaterally and the bone is removed completely. Care is taken to preserve the facet joints, as removal of bilateral facets can introduce instability[11].

Data did not fit the assumption of normal distribution; therefore, Wilcoxon rank-sum tests were used to compare difference of Karnofsky and Nurick score between laminoplasty and laminectomy groups; Wilcoxon signed rank tests were used to compare difference between pre- and post-operative condition by Karnofsky and Nurick scales for each of the patient groups. To test the association of GOS and Rankin score with group outcomes, chi-square tests were applied. $p<0{\cdot}05$ was considered statistically significant. Analyses were performed using SAS (version 9·1, SAS Institute, Cary, NC, USA).

Results

There were 72 laminoplasty and 49 laminectomy patients. In the laminoplasty group, there were 48 men and 29 women. In the laminectomy group, there were 35 men and 14 women. The mean age of the laminoplasty patients was 59·7 years (range: 32–85 years), while the median age of laminectomy patients was 57·3 years (range: 23–88 years).

For both procedures, no patient suffered a clinical deterioration. There was no mortality or permanent morbidity in this study. Among the cervical laminoplasty patients, there were one infection and one minor dehiscence that required application of additional sutures compared with the cervical laminectomy (CLX) patients who had two infections and one minor dehiscence that required additional sutures.

Laminoplasty patients had greater improvement according to the Rankin score ($p<0{\cdot}0001$, chi-square test). The Rankin score had no improvement in 1·4% of laminoplasty and 22·5% laminectomy patients; 94·3% laminoplasty and 77·5% laminectomy patients improved by 1, 2 or 3 (*Figure 1*); 4·2% laminoplasty and 0% laminectomy patients improved by 4. Laminoplasty patients had better improvement according to GOS ($p<0{\cdot}0027$, chi-square test). The GOS had no change after 6·9% laminoplasty and 28·6% laminectomy patients (*Figure 2*). Laminoplasty patients also displayed greater increase in Karnofsky score between pre-operative and post-operative status ($p<0{\cdot}01$, Wilcoxon test). The Karnofsky score had no improvement in 1·4% laminoplasty and 16·3% laminectomy patients. Ninety-three percent laminoplasty and 83·7%

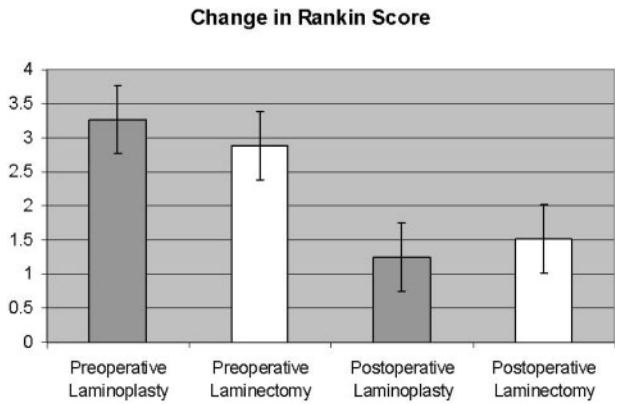

Figure 1 Change in Rankin score ($p<0{\cdot}0001$)

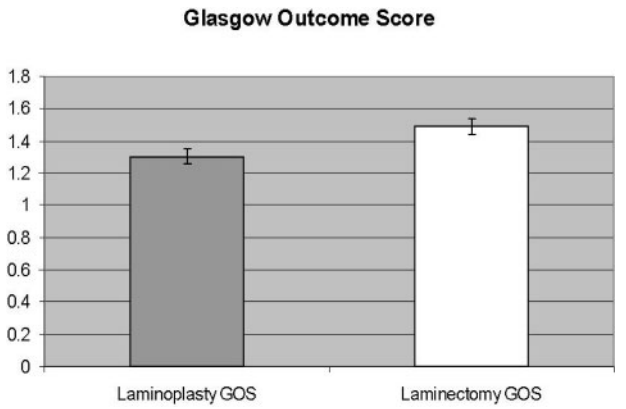

Figure 2 Glasgow outcome score ($p<0{\cdot}0027$)

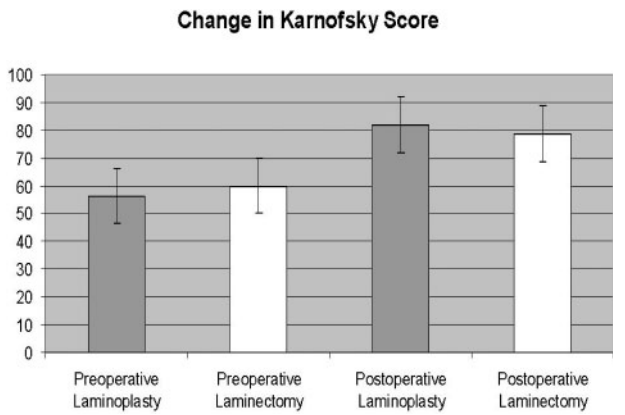

Figure 3 Change in Karnofsky score ($p<0{\cdot}01$)

laminectomy improved by 10, 20, 30 or 40, and 5·6% laminoplasty and 0% laminectomy improved by 50 or 60 (*Figure 3*). The mean change in Nurick scores was not significant between the groups ($p<0{\cdot}62$, Wilcoxon test; *Figure 4*). Laminoplasty patients with a worse pre-operative status had a greater relative function improvement after surgery than the laminectomy patients. For both procedures, patients with worse myelopathy symptoms pre-operatively had greater relative improvement after surgery.

Considering pain management after surgery, 34 laminoplasty patients (47%) received intravenous narcotics more than 48 hours after surgery, while 39 (53%) did not; 29 laminectomy patients (63%) required intravenous narcotics more than 48 hours

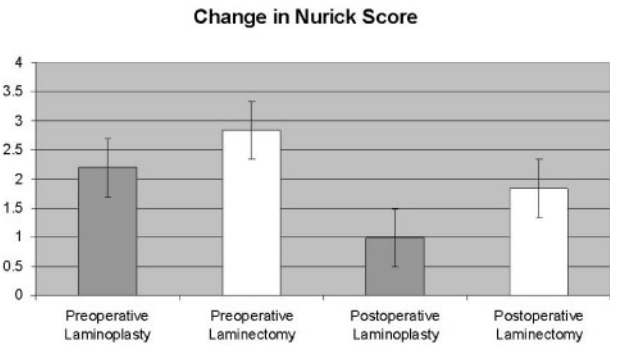

Figure 4 Change in Nurick score ($p<0{\cdot}62$)

after surgery, while 20 (37%) did not ($p=0{\cdot}17$, chi-square test).

Among laminoplasty patients, the average length of hospital stay was 6·6 ($\pm$5·7) days, whereas for CLX, it was 8·4 ($\pm$6) days (*Figure 5*; $p=0{\cdot}04$, Wilcoxon rank-sum test). The discharge disposition was the same in both groups. In the laminoplasty group, 54 patients (75%) were discharged home, 13 patients (18%) had inpatient rehabilitation and five patients (7%) went to a nursing home. Whereas in the laminectomy group, where 35 patients (72%) were discharged home, nine patients (18%) had inpatient rehabilitation and five patients (10%) went to a nursing home. By 4 months, all patients were at home regardless of the procedure.

Discussion

Both procedures were safe and effective treatments for cervical radiculopathy and myelopathy. Patients who underwent laminoplasty had a better functional outcome at 4 months after surgery, measured by a greater improvement of the GOS, Karnofsky scale and Rankin scale. The degree of improvement of myelopathy (Nurick score) was the same for both procedures. Patients were discharged home earlier after laminoplasty than after laminectomy, and tended to suffer less post-operative pain. This result makes empirical sense: both procedures provide good neural decompression, but the laminoplasty procedure is less destructive to tissues and tends to heal better that laminectomy. The opportunity for muscle to reattach to bone and the preservation of bony

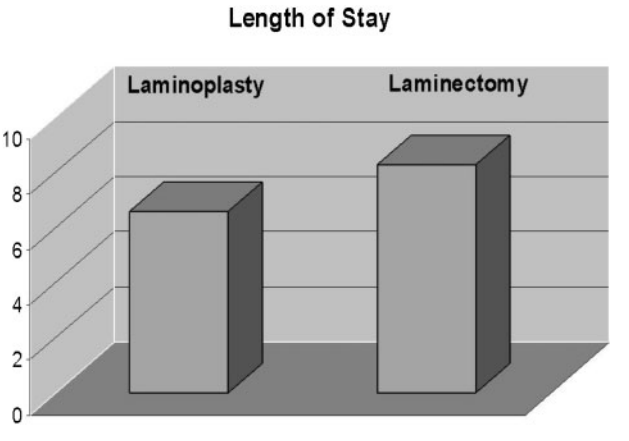

Figure 5 Length of stay in days ($p=0{\cdot}04$)

Published by Maney Publishing (c) W. S. Maney & Son Limited

Published by Maney Publishing (c) W. S. Maney & Son Limited

covering of the dura may contribute to a more rapid recovery.

A study by Heller *et al.* looked at treatment of cervical myelopathy with laminoplasty or laminectomy using the Nurick scale[12]. They also studied pre-operative radiographs and followed up with their patients an average of 25·9 days later in the clinic to evaluate functional outcome and post-operative radiographs. That study had 25 patients in each group and found that patients reported functional improvement of 0·7 points for the laminectomy group versus 1·2 points for the laminoplasty group ($p>0{\cdot}05$), and there were no complications in the laminoplasty group. In the laminectomy group, there were 14 complications in nine patients. The Heller study is similar to ours in concluding that laminoplasty is a comparable procedure with a better functional outcome, due to many similarities in the study design. Their Nurick score had a significant difference compared with our study. This study also saw many more complications in their laminectomy patients. In the Heller study, laminectomy was also accompanied by fusion, a more extensive procedure that may add to the perioperative risks. The earlier follow-up may have contributed to the greater difference between the procedures, lending additional support to the hypothesis that laminoplasty patients recover faster than those who had laminectomy.

Our current chart review-based study was not designed to investigate long-term outcome. This may be one reason why the improvement of myelopathy symptoms was not different between the groups. A study by Kaminsky *et al.* also looked at treatment of cervical myelopathy with laminoplasty or laminectomy using a modified Nurick scale[13]. They followed the patients for 5 years on average and found a markedly better long-term improvement of myelopathy after laminoplasty than after laminectomy.

The Rankin scale was developed to assess stroke patients. However, it has been used before to study the surgical outcome of laminoplasty in obese patients[14]. Thus, we felt that it had some prior validation.

One of the stimuli for our study was a review article by Ratliff *et al.*, which compared laminoplasty and laminectomy by doing a meta-analysis of 71 retrospective studies[15]. They looked at 2000 patients in studies that used the Japanese Orthopaedic Association Scale or Nurick scale and found that there was no significant difference in neurological outcome between laminoplasty and laminectomy. They also reported that laminoplasty patients had a decreased range of motion compared to laminectomy patients. This has not been our subjective experience, although our current study could not address this question, being limited to existing information in the chart. The limitations of this study are the selection of studies to include in the review article and the type of question asked. For example, the Kaminsky article is more recent than the meta-analysis and was not included. The only question in all the papers was the long-term neurological outcome. We believe that there is another aspect to consider when choosing a surgical approach: functional recovery from surgery. The authors of the review did not address the question of early outcomes or recovery time after surgery, which is the focus of our study.

Newer techniques for treatment of cervical spondylotic myelopathy are currently in use. In a review article by Komotar *et al.*, laminectomy with lateral mass fixation is presented as the preferred technique for cervical spondylotic myelopathy[16]. In a study by Matsumura *et al.*, laminoplasty was combined with lateral mass fixation in patients with multiple segment spondylotic cervical canal stenosis[17]. Adding instrumentation increases the cost and the operative time. Although instrumentation may be preferred in selected cases, the routine use of instrumentation may not be necessary since laminoplasty appears safe and effective and does not require instrumentation[12].

Although cervical laminoplasty was developed with the goal of improving the long-term biomechanical outcome of cervical spine decompression, the procedure appears to have additional benefits in the short and medium term. We speculate that the immediate symptomatic and functional advantage of laminoplasty seen in our study and in the experience of others is related to the relative preservation of the bony cover of the thecal sac. At the completion of a laminoplasty, the dural surface is largely covered with bone, and the muscle lies mostly on the bone. Muscle contractions reinforce the construct[7]. The muscle does not compress the thecal sac and spinal cord even when it swells post-operatively. Any blood coming from the muscle is tamponaded by the bone, rather than by compression against the thecal sac. Attachment of muscles and scar to the thecal sac is largely avoided. In our experience, an important reason in choosing laminoplasty over laminectomy is the better and quicker symptomatic and functional recovery.

Although the patients were not randomized, the two groups were very similar in key parameters: age, diagnoses and symptoms. A review of the patient charts was carried out by independent observers, and the scales used were applied objectively. The patients were chosen for the laminoplasty or laminectomy procedure by surgeon preference. Some of the surgeons performed laminoplasty and others laminectomy for the same indication. The same residents and nurse practitioners were involved in the surgery and post-operative management with the same team rounding on all of the patients with the same discharge indications.

This is a retrospective study; thus, selection biases cannot be totally avoided, particularly surgeon preferences. However, rather than the same surgeon selecting one procedure or the other for a particular patient, which would have introduced a certain bias, each surgeon performed a particular procedure for all patients. It is still possible that the difference in the speed of recovery of the patients in different groups was related to a difference either in patient population or the surgeon's skill. However, all the surgeons were on the faculty at the University of Illinois at Chicago with extensive experience in cervical spine

surgery, and the patients all came from the same clinic population. Therefore, we believe that the bias in our study was as small as possible in a retrospective study. In any retrospective study, selection bias cannot be avoided, but we believe that, in our case, most of the difference in outcome was related to the choice of procedure. The patient discharge practices at our institution at that time resulted in relatively long hospital stays. It is possible that the difference between the two patients groups was easier to measure than in cases where there is a greater pressure to discharge early. This study was not designed to answer any question regarding the chronic effect of these procedures, already well addressed by other studies with longer follow-up[2,8].

Conclusion

Both cervical laminectomy and laminoplasty are safe and effective for the treatment of cervical myelopathy or radiculopathy. Cervical laminoplasty results in a shorter hospital stay and greater functional improvement at 4 months follow-up, suggesting faster recovery. Therefore, our results support the hypothesis that patients experience a greater early recovery of function after laminoplasty than after laminectomy. We speculate that this finding will hold for patients who had instrumented fusion at the time of their laminectomy. We further speculate that the preservation of the bony cover of the spinal canal is responsible for this benefit of laminoplasty.

References

1 Bhardwaj A, Long DM, Ducker TB, *et al.* Neurologic deficits after cervical laminectomy in the prone position. *J Neurosurg Anesthesiol* 2001; **13**: 314–319.

2 Chiba K, Ogawa Y, Ishii K. Long-term results of expansive open-door laminoplasty for cervical myelopathy – average 14-year follow-up study. *Spine* 2006; **31**: 2998–3005.

3 Cybulski GR, D'Angelo CM. Neurological deterioration after laminectomy for spondylotic cervical myeloradiculopathy: The putative role of spinal cord ischemia. *J Neurol Neurosurg Psychiatry* 1988; **51**): 717–718.

4 Guigui P, Benoist M, Deburge A. Spinal deformity and instability after multilevel cervical laminectomy for spondylotic myelopathy. *Spine* 1998; **23**: 440–447.

5 Lonstein J, Winter R, Moe J, *et al.* Post-laminectomy spine deformity. *J Bone Joint Surg* 1976; **58**: 727.

6 Oyama M, Hattori S, Moriwaski N, *et al.* A new method of cervical laminectomy. *Chubu Seisei-shi* 1973; **16**: 792–794.

7 Hirabayashi K, Watanabe K, Wakano K, *et al.* Expansive open-door laminoplasty for cervical spinal stenotic myelopathy. *Spine* 1983; **8**: 693–699.

8 Ogawa Y, Chiba K, Matsumoto M, *et al.* Long-term results after expansive open-door laminoplasty for the segmental-type of ossification of the posterior longitudinal ligament of the cervical spine: A comparison with nonsegmental-type lesions. *J Neurosurg Spine* 2005; **3**: 198–204.

9 Wang MY, Shah S, Green BA. Clinical outcomes following cervical laminoplasty for 204 patients with cervical spondylotic myelopathy. *Surg Neurol* 2004; **62**: 487–492.

10 Bonita R, Beaglehole R. Modification of Rankin scale: Recovery of motor function after stroke. *Stroke* 1988; **19**: 1497–1500.

11 Schmidek H, Sweet W. *Operative Neurosurgical Techniques: Indications, Methods, and Results*, Philadelphia, PA: W. B. Saunders Company, 2000.

12 Heller JG, Edwards CC, 2nd, Murakami H, *et al.* Laminoplasty versus laminectomy and fusion for multilevel cervical myelopathy: An independent matched cohort analysis. *Spine* 2001; **26**: 1330–1336.

13 Kaminsky SB, Clark CR, Traynelis VC. Operative treatment of cervical spondylotic myelopathy and radiculopathy. A comparison of laminectomy and laminoplasty at five year average follow-up. *Iowa Orthop J* 2004; **24**: 95–105.

14 Ain MC, Chang TL, Schkrohowsky JG. Laminectomies and achondroplasia: Does body mass index influence surgical outcomes? *Am J Med Genet A* 2007; **143**: 1032–1037.

15 Ratliff JK, Cooper PR. Cervical laminoplasty: A critical review. *J Neurosurg* 2003; **98** (3 Suppl): S230–S238.

16 Komotar RJ, Mocco J, Kaiser MG. Surgical management of cervical myelopathy: Indications and techniques for laminectomy and fusion. *Spine J* 2006; **6** (6 Suppl.): S252–S267.

17 Matsumura A, Yanaka K, Akutsu H, *et al.* Combined laminoplasty with posterior lateral mass plate for unstable spondylotic cervical canal stenosis – technical note. *Neurol Med Chir (Tokyo)* 2003; **43**: 514–519.

Published by Maney Publishing (c) W. S. Maney & Son Limited